

Randomized study on effect of conventional versus Schlosser's fabrication techniques for complete over dentures supported by mandibular implants

Noha Aligamaleldin Abdelaal

Department of Prosthodontics, Faculty of Oral and Dental Medicine, Cairo University, Cairo, Egypt

Keywords

Complete denture, dental implant, mandibular overdenture, marginal bone loss, Schlosser's technique

Correspondence

Noha Aligamaleldin Abdelaal, 4 Gamal Salem St. Dokki, Giza 12311, Egypt. Email: noha.agamaleldin@dentistry.cu.edu.eg

Received 15 May 2017;

Accepted: 25 July 2017

doi: 10.15713/ins.idmjar.70

Abstract

Background: The conventional method of complete denture fabrication has many problems that include lack of uniform distribution of occlusal forces to the basal seat, causing inflammation, ulcers in the supporting tissues, more rapid residual ridge resorption, increase patient discomfort, increase parafunctional movements, and the need for frequent adjustments.

Aim: The aim of this study is to evaluate and compare the effect of two different fabrication techniques for complete over dentures supported by mandibular implants.

Methodology: A total of 24 edentulous subjects were eligible for inclusion. Using a random sampling system, conventional or Schlosser's technique was used to fabricate the dentures. Two implants were placed in the canine area of all patients. After 3 months, ball attachments were connected to the implants, and the denture delivered with the retentive components incorporated in the denture base. At the follow-up examinations, implant stability and marginal bone loss were evaluated at 3, 6, and 12 months.

Results: The sample of 24 patients, with a mean age of 55.2 years, was included in this study. All patients attended the 12-month follow-up. The complete denture fabricated by Schlosser's technique showed significant more implant stability and less bone loss when compared to conventionally fabricated dentures.

Conclusion: The Schlosser's technique is considered as predictable methods of complete denture construction. Consequently, this technique has a positive effect on the implants that supported mandibular overdenture. The more harmonious occlusion result from this technique results in better implant stability and decreases the rate of bone loss around the implants.

Clinical Significance: The denture fabricated with Schlosser's technique results in more harmonious occlusion that suggested as one requirement of successful dental implants.

Introduction

A complete denture and consequently an overdenture face a number of problems if there is an uneven or interceptive contact in centric relation.^[1]

These problems include lack of uniform distribution of occlusal forces to the basal seat, causing inflammation, ulcers in the supporting tissues, more rapid residual ridge resorption, increase patient discomfort, increase parafunctional movements, and the need for frequent adjustments.^[2-4]

In implants-supported overdenture, the implants primary stability has been acknowledged as the essential criterion for the

success of osseointegration and consequently the prosthodontic implant therapy.^[5,6]

Attachment of implants to bone is said to be rigid, but still, a displacement is permitted in vertical direction and lateral direction. This displacement, causing microtrauma in bone, is counteracted continuously by bone reparative and remodeling capacities.^[7]

The concept of peri-implant reaction to occlusal discrepancies and consequently excessive occlusal load is currently still missed. The fatigue microtrauma phenomenon was introduced due to the progressive bone loss happening in the cervical area due to occlusal overload. The resultant bone level loss, happening when

rate of reparative bone is less than rate of fatigue micro damage, is negatively affecting the implant stability and consequently affects its prognosis.^[8]

Clinical remount procedures have been conducted by researchers for its effect on eliminating uneven occlusal contact for better denture prognosis.^[9]

Laboratory remounting is an imperative advantageous step for easily spotting errors on the articulator rather than in the patient's mouth and maintaining the desired tooth morphology that needs to be followed after processing of the denture.^[10]

Schlosser's technique was introduced by Rudolph Oscar Schlosser, as a solution for further occlusal adjustments for complete dentures that proved to decrease the occlusal discrepancies.^[11]

The aim of this study was to compare the effect of conventional and Schlosser's denture construction techniques on the marginal bone level and implant stability.

Materials and Methods

The study was designed to be a parallel randomized controlled trial.

The study protocol was approved by the Prosthodontic Department Board and Ethics Committee of Faculty of Oral and Dental Medicine, Cairo University.

Selection criteria

A total of 24 completely edentulous patients were selected from the outpatient clinic of the Prosthodontics Department, Faculty of Oral and Dental Medicine, Cairo University, in the period between March 2015 and August 2016.

The inclusion criteria for this study include patients those were as follows:

- Completely edentulous with ability to provide informed consent.
- Age ranged from 45 to 60 years.
- Free from a systemic disease that could affect the implant osseointegration such as diabetes mellitus and osteoporosis.
- Free from any oral pathological lesions in the oral cavity such as cysts, remaining root, or residual infection.
- Free from temporomandibular or muscular disorders.

Smokers, patients with a history of bruxism or clenching and those with skeletal Class 2 or Class 3 relationship were excluded from the study.

Patient examination

An initial evaluation was conducted to determine whether the patient met the study inclusion criteria. This evaluation consisted of a medical history questionnaire, a clinical examination, and radiographic assessment.

Informed consent

All patients were requested to sign an informed consent that was translated into Arabic language to be understood by the

patients. The trial conducted in accordance with the Declaration of Helsinki (version 2008).

Patients grouping (randomization process)

The 20 patients were randomly assigned into two identical groups each of which 12 patients using, especially website concerned with randomization process called research randomizer (<https://www.randomizer.org/>).

- Group 1 (intervention Group): 12 completely edentulous patients that were received conventionally fabricated complete dentures with lower denture supported by mandibular implants and ball attachments.
- Group 2 (control Group): 12 completely edentulous patients that were received complete dentures fabricated using "Schlosser's Technique" (i.e., try-in stage is followed by completed construction of upper denture then readjusting occlusion of lower trial denture base against the remounted upper processed denture).

Then, the random generated numbers were saved in opaque sealed envelopes.

Interventions and study procedures

Surgical procedure

Every patient received two root-form endosseous implant 3.7 mm width with ball attachment 2.5 diameters is placed in the mandibular canines area and left unloaded 3 months to osseointegrate.

The procedures done as follow: The surgical stent was placed, and locator drill was used to determine the point of entry. Then, drilling of the osteotomy site was performed by surgical drills in a sequential manner following manufacture directions. The parallel pin was placed and the stent was repositioned to ensure proper alignment of the osteotomy site.

The drilling process was accompanied with copious sterile saline irrigation. After drilling with a final drill, a root form self-tapping implant (ZimmerInc., TSV, Carsbad, CA, USA) with proper length and width according to pre-surgical planning was installed into the osteotomy with a torque wrench, and the cover screw was placed. Flap was repositioned properly and sutured using 000 black silk in an interrupted manner.

After 3 months, 2nd stage surgery was carried out. The surgical stent was used to determine the position of the implant with the aid of the periodontal probe after giving infiltration anesthesia. A minimal crestal incision was made to uncover the dental implant. Cover screw removed, then the implant stability was measured, for both groups, with Osstell device (OsstellTM, Integration Diagnostics Ltd., Goteborgsvagen, Sweden) (i.e., measure implant stability quotient [ISQ] value).

Healing abutments were placed for 2 weeks. After that, the ball (Zimmer, dental Tapered screw BACW4) attachment with proper height was used according to peri-implant mucosal height. The ball attachment carefully held and threaded into the implant fixture using torque wrench up to 35 N.

Complete denture construction

A conventional complete denture was constructed for Group 1 patients, following the traditional steps. For Group 2, complete dentures fabricated using "Schlosser's Technique" (i.e., try-in stage is followed by completed construction of upper denture then readjusting occlusion of lower trial denture base against the remounted upper processed denture) [Figure 1].

Finally, the construction of lower complete denture was performed.

The ball cap attachments were picked up intraorally using cold-curing resin (Rebaron self-cured acrylic (GC Cooperation, Tokyo, Japan) as follow:

The block out spacers were slipped around the ball abutments. The metal housing was placed directly over the ball abutments [Figure 2] then the dentures were properly relieved opposite to the attachment sites and assured for proper seating as proved by the absence of rocking and proper occlusion.

A small hole was done at the lingual flange to allow for escaping of excess cold cured polymerizing resin. Cold-cured resin was mixed according to manufacture instruction and then placed in the relieved two areas of the denture, and the denture




Figure 1: The processed upper denture is remounted against the waxed lower denture

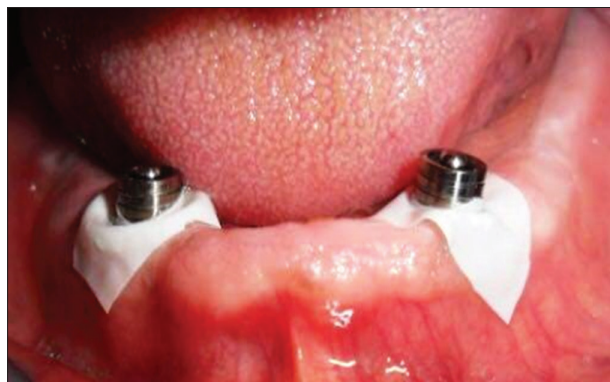

Figure 2: Metal housing placed on the ball attachment

was seated in the patient mouth. The resin was left to polymerize while the patient was closing in the centric jaw relation.

The denture was removed, trimmed, and polished with the metal housings picked up in its fitting surface [Figure 3].

The adaptation on the residual ridges was then checked and adjusted if necessary, and the patient dismissed. No limitations to chewing function were given.

The patients followed up at 3, 6, and 12 months after implant loading to measure outcomes.

Implant stability measurement

Immediately after the implant placement, implant stability was performed using the Ostell Monitor. The resonance frequency (RF) value was measured 4 times in four directions, buccal, lingual, mesial, and distal to each implant. RF values were represented by a quantitative unit called the ISQ on a scale from 1 to 100. This procedure was repeated at 3, 6, 9, and 12 months.

Assessment of the marginal bone loss

Direct digital radiography using digora computerized system was applied.

Standardized periapical radiography was performed using an extension cone paralleling technique sensor holder with a customized personalized bite registration record, made from putty rubber base impression material.

All the periapical radiographic exposures were made with the same dental long cone X-ray unit with similar exposure factors (70 kV), 6 mA with a focal distance of 35 cm using the same sensor.

Imaging was performed for the 12 patients at the 3, 6, and time months to calculate the marginal bone loss.

Marginal bone loss measurements were as follows: A line tangential to the apex and perpendicular to the long axis of the implant was 1st drawn, another line was extended from the alveolar crest to the 1st line and was drawn tangential to the flutes of the implant on the mesial and distal aspect.

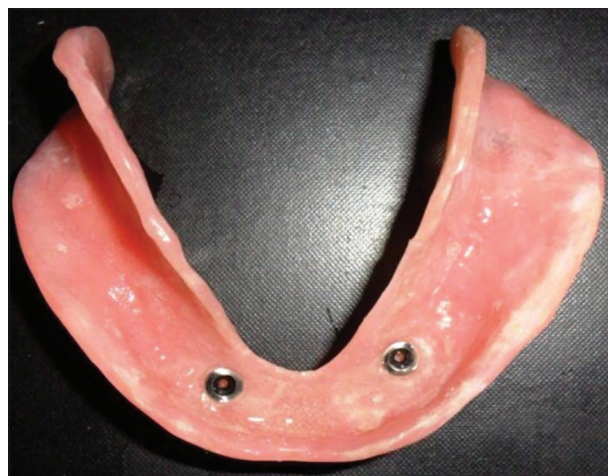

Figure 3: The fitting surface of the lower overdenture

The mean values of the mesial and distal bone loss measurements for each implant during the follow-up intervals were calculated.

Results

The samples of 24 patients with a mean age of 55.2 years were included in this study. A total of 48 implants were placed (24 in Group 1 and 24 in Group 2). All patients attended the 12-month follow-up.

Implant stability

There was statistically significant difference between Group 1 (70.46 ± 1.97) and Group 2 (72.42 ± 3.56), where P = 0.008 [Table 1 and Graph 1].

Marginal bone loss measurements

It was found that the marginal bone loss in the 1st group was significantly lower than the 1st Group [Table 2].

Discussion

In this study, selection criteria excluded patients with systemic diseases that may interfere with bone quality, normal healing mechanism, osseointegration of the implants, and proper bone response to the applied forces.^[12,13]

Patients with bruxism or grinding habits were totally excluded to avoid undue force concentration, especially, horizontal

stresses on the osseointegrated implants which might affect the overall results.^[14]

The smoking habit was considered as exclusion factor because the smoking significantly affects the implant failure rates, the incidence of postoperative infections, as well as the marginal bone loss as revealed by a recent systematic review.^[15] An added failure rate of about 8% was noticed in smokers that occurred either at the implant exposure or after a short time of implant loading.^[16]

In this study, the effect of conventional versus Schlosser's techniques during complete denture construction was compared to evaluate the effect of these different approaches on the implant stability and marginal bone loss. Complete dentures fabricated using "Schlosser's Technique" in which the try-in stage is followed by completed construction of upper denture then readjusting occlusion of lower trial denture base against the remounted upper processed denture, and finally, the construction of lower complete.

There was a statistically significant difference in decrease in bone height measurements at 3-, 6-, and 12-month follow-up periods. This may be due to better stress distribution of local in the second group due to loss occlusal discrepancies, consequently minimizing the amount of bone resorption and better preservation of the alveolar bone.^[17] The mean marginal bone loss over the follow-up period was 1 mm in conventional group and only 0.39 mm in test group with mean difference of 0.61 mm that is clinically significant as clarified by Ahlqvist *et al.*,^[18] in their a 2-year study, they stated that if the difference is >0.47 mm, the differences in bone levels were noted and can be identified.

Khamis *et al.*^[19] compared the effects of 3 occlusal forms on the implant supporting tissues in patients with mandibular implant overdentures. They found that the different occlusal forms 0°, 30°, and lingual contact (lingualized occlusion) were not found to have a clinically detrimental effect on the peri-implant soft or hard tissues.

The primary stability at implant installation is achieved by the mechanical integration between the surgically created bone bed and the implant, which is dependent from the implant design,

Table 1: The mean±SD values of implant stability in both groups

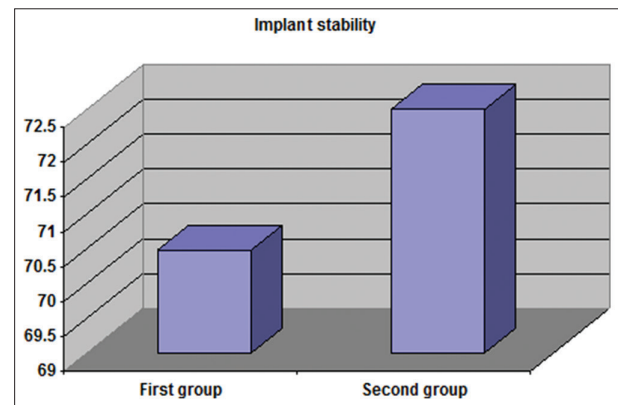
Variables	Implant stability (RF) (Mean±SD)
Group 1	70.47±1.97
Group 2	72.49±3.56
P-value	0.008

RF: Resonance frequency, SD: Standard deviation

Table 2: The mean±SD values of peri-implant marginal bone loss measured in mm for both groups

Groups	3 M	6 M	12 M
Group 1			
Range	0.1-0.4	0.3-0.5	1.04-1.09
Mean±SD	0.263±0.082	0.413±0.085	1.068±0.016
P ₁		0.0012*	0.001*
P ₂			0.0052*
Group 2			
Range	0.1-0.3	0.1-0.5	0.35-0.70
Mean±SD	0.171±0.069	0.283±0.096	0.39±0.100
P ₁		0.002	0.001*
P ₂			0.013*

SD: Standard deviation. *P<0.05 show statistically significant



Graph 1: The mean values of implant stability in both groups

the surgical technique, and the bone quality. The secondary stability is affected by an incremental degree of bone-to-implant contact.^[20] Less occlusal discrepancies in the 2nd Group is associated with good implant stability and minimal marginal bone loss which are indicators of a better osseointegration.^[21]

Peroz *et al.*^[22] performed a randomized, clinical trial comparing two occlusal schemes, balanced occlusion, and canine guidance, in 22 patients with conventional complete dentures. The results of the assessment using a implant stability revealed that canine guidance was comparable to balanced occlusion in denture retention, esthetic appearance, and chewing ability.

Conclusion

The Schlosser's technique is considered as predictable methods of complete denture construction. Consequently, this technique has a positive effect on the implants that supported mandibular overdenture. The more harmonious occlusion result from this technique results in better implant stability and decreases the rate of bone loss around the implants.

Reference

1. Ortman HR. The role of occlusion in preservation and prevention in complete denture prosthodontics. *J Prosthet Dent* 1971;25:121-38.
2. Lefebvre CA. In: Zarb GA, Bolender CL, Hickey JC, Carlsson GE, editors. *Boucher's Prosthodontic Treatment for Edentulous Patients*. Saint Louis: CV Mosby; 1990. p. 623.
3. Firtell DN, Finzen FC, Holmes JB. The effect of clinical remount procedures on the comfort and success of complete dentures. *J Prosthet Dent* 1987;57:53-7.
4. Javed F, Ahmed HB, Crespi R, Romanos GE. Role of primary stability for successful osseointegration of dental implants: Factors of influence and evaluation. *Interv Med Appl Sci* 2013;5:162-7.
5. Alqutaibi AY, Kaddah AF, Farouk M. Randomized study on the effect of single-implant versus two-implant retained overdentures on implant loss and muscle activity: A 12-month follow-up report. *Int J Oral Maxillofac Surg* 2017;46:789-97.
6. Bischof M, Nedir R, Szmukler-Moncler S, Bernard JP, Samson J. Implant stability measurement of delayed and immediately loaded implants during healing. *Clin Oral Implants Res* 2004;15:529-39.
7. Hoshaw SJ, Brunski JB, Cochran GV. Mechanical loading of bränemark implants affects interfacial bone modeling and remodeling. *Int J Oral Maxillofac Implants* 1994;9:345-60.
8. Isoda K, Ayukawa Y, Tsukiyama Y, Sogo M, Matsushita Y, Koyano K. Relationship between the bone density estimated by cone-beam computed tomography and the primary stability of dental implants. *Clin Oral Implants Res* 2012;23:832-6.
9. Alqutaibi A, Aboalrejal A. Types of occlusal splint in management of temporomandibular disorders (TMD). *J Arthritis* 2015;4:1-4.
10. Shigli K, Angadi GS, Hegde P. The effect of remount procedures on patient comfort for complete denture treatment. *J Prosthet Dent* 2008;99:66-72.
11. Schlosser RO, Gehl DH. *Complete Denture Prosthesis*. Philadelphia, PA: WB Saunders; 1953.
12. Michaeli E, Weinberg I, Nahlieli O. Dental implants in the diabetic patient: Systemic and rehabilitative considerations. *Quintessence Int* 2009;40:639-45.
13. Mombelli A, Cionca N. Systemic diseases affecting osseointegration therapy. *Clin Oral Implants Res* 2006;17 Suppl 2:97-103.
14. Manfredini D, Poggio CE, Lobbezoo F. Is bruxism a risk factor for dental implants? A systematic review of the literature. *Clin Implant Dent Relat Res* 2014;16:460-9.
15. Chrcanovic BR, Albrektsson T, Wennerberg A. Smoking and dental implants: A systematic review and meta-analysis. *J Dent* 2015;43:487-98.
16. De Bruyn H, Collaert B. The effect of smoking on early implant failure. *Clin Oral Implants Res* 1994;5:260-4.
17. Wyatt CC. The effect of prosthodontic treatment on alveolar bone loss: A review of the literature. *J Prosthet Dent* 1998;80:362-6.
18. Ahlqvist J, Borg K, Gunne J, Nilson H, Olsson M, Astrand P. Osseointegrated implants in edentulous jaws: A 2-year longitudinal study. *Int J Oral Maxillofac Implants* 1990;5:155-63.
19. Khamis MM, Zaki HS, Rudy TE. A comparison of the effect of different occlusal forms in mandibular implant overdentures. *J Prosthet Dent* 1998;79:422-9.
20. Alqutaibi AY. Cement-and screw-retained implant-supported restorations showed comparable marginal bone loss and implant survival rate. *J Evid Based Dent Pract* 2017;17:107-9.
21. Alqutaibi AY. Limited evidence suggests a single implant overdenture as an alternative to two-implant-supported mandibular overdentures. *J Evid Based Dent Pract* 2016;16:44-6.
22. Peroz I, Leuenberg A, Haustein I, Lange KP. Comparison between balanced occlusion and canine guidance in complete denture wearers - A clinical, randomized trial. *Quintessence Int* 2003;34:607-12.

How to cite this article: Abdelaal NA. Randomized study on effect of conventional versus Schlosser's fabrication techniques for complete over dentures supported by mandibular implants. *Int Dent Med J Adv Res* 2017;3:1-5.

This work is licensed under a Creative Commons Attribution 4.0 International License. The images or other third party material in this article are included in the article's Creative Commons license, unless indicated otherwise in the credit line; if the material is not included under the Creative Commons license, users will need to obtain permission from the license holder to reproduce the material. To view a copy of this license, visit <http://creativecommons.org/licenses/by/4.0/> © Abdelaal NA. 2017